

Clinical Impression of the Efficacy of Eyelid Warming or Lid Hygiene as Treatment for Meibomian Gland Dysfunction

Reiko Arita^{1,2*}, Motoko Kawashima^{1,3} and Naoyuki Morishige^{1,4}

¹Lid and Meibomian Gland Working Group (LIME), Saitama, Japan

²Itoh Clinic, Saitama, Japan

³Department of Ophthalmology, Keio University, Tokyo, Japan

⁴Division of Cornea and Ocular Surface, Ohshima Eye Hospital, Fukuoka, Japan

*Corresponding author: Reiko Arita, Department of Ophthalmology, Itoh Clinic, 626-11 Minami-Nakano, Minumaku, Saitama, Saitama 337-0042, Japan, E-mail: ritoh@za2.so-net.ne.jp

Received date: August 15, 2018; Accepted date: September 24, 2018; Published date: September 28, 2018

Copyright: ©2018 Arita R, et al. This is an open-access article distributed under the terms of the Creative Commons Attribution License, which permits unrestricted use, distribution, and reproduction in any medium, provided the original author and source are credited.

Abstract

Objective: Eyelid warming and lid hygiene are recommended for first-line treatment of meibomian gland dysfunction (MGD). We administered a questionnaire to ophthalmologists in Japan regarding their impressions of the clinical usefulness of noncontact meibography as well as the clinical efficacy of eyelid warming and lid hygiene for the diagnosis and management of MGD patients.

Methods: A total of 121 physicians (87 men and 34 women, mean age of 51.9 ± 11.2 years) responded to the online questionnaire, with 22, 74, and 60 responding to the questions on meibography, eyelid warming, and lid hygiene, respectively.

Results: Noncontact meibography was considered notably useful for diagnosis of MGD or for education of MGD patients by 72.7% and 81.8% of respondents, respectively. Eyelid warming was considered valuable for the treatment of MGD and at least somewhat effective for reducing the use or prescription of eyedrops by 51.4%, 71.7%, and 66.2% of respondents, respectively. Lid hygiene was recognized as valuable for the treatment of MGD and at least somewhat effective for reducing the use or prescription of eyedrops by 63.3%, 68.3%, and 68.3% of respondents, respectively. Combined treatment with eyelid warming and lid hygiene was recommended by 51.7% of respondents for >80% of patients.

Conclusion: Noncontact meibography, eyelid warming, and lid hygiene were recognized as effective by Japanese physicians. The recommendation of self-care consisting of eyelid warming or lid hygiene has the potential to reduce the cost of medical care for patients with MGD.

Keywords: Meibomian gland; Meibomian gland dysfunction; Meibography; Warming compress; Lid hygiene; Self-care; Education; Dry eye

Introduction

Meibomian glands are large sebaceous glands located in the eyelids and secrete lipid (meibum) that prevents excessive evaporation of the tear film [1]. Meibomian gland dysfunction (MGD) is defined as a chronic abnormality of meibomian glands characterized by terminal duct obstruction or qualitative or quantitative changes in the glandular secretion that can result in changes to the tear film, inflammation, ocular surface disease, or symptoms of eye irritation [2]. MGD is a leading cause of the entire dry eye, not only the evaporative dry eye [3]. The ocular symptoms of MGD are similar to those of aqueous-deficient dry eye and include fatigue as well as foreign body, burning, and itchy sensations. However, the clinical findings of MGD differ from those of aqueous-deficient dry eye [4]. The first line of treatment for MGD has been proposed to include patient education, the application of a warming compress, and the practice of lid hygiene [5]. In clinical practice, many ophthalmologists also tend to prescribe eye

drops developed for aqueous-deficient dry eye as a result of the similarity in symptoms with MGD.

In the present study, we administered a questionnaire regarding the diagnosis and treatment of MGD to physicians with an interest in this condition in order to evaluate the perceived usefulness of noncontact meibography and the efficacy of self-care consisting of the application of a warming compress or the practice of lid hygiene. Our results suggest that appropriate diagnosis and management not only contribute to the success of MGD treatment but also avoid unnecessary prescription of eye drops.

Subjects and Methods

The Lid and Meibomian Gland Working Group (LIME; <http://www.lime.jp>) was established in 2012 for ophthalmologists in Japan with an interest in MGD. Its purpose is to educate not only physicians but also patients with regard to the high prevalence of MGD and the importance of its proper diagnosis and treatment (<http://www.lime.jp/en/about>). We made available a questionnaire in Google format to be completed by LIME members on a volunteer basis and with complete anonymity between April and June 2018. A total of 121

LIME members (87 men and 34 women with a mean \pm SD age of 51.9 \pm 11.2 years; 99 employed in private clinics and 22 in public hospitals) responded to the Web-based questionnaire. The content of questionnaire is described in Figures 1 and 2.

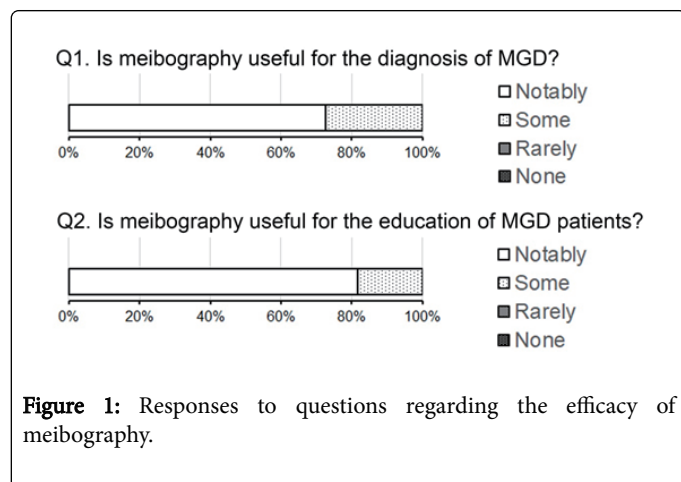


Figure 1: Responses to questions regarding the efficacy of meibography.

Results

Meibography

First, we asked ophthalmologists the efficacy of meibography in their clinics. Meibography is an observation device to visualize meibomian gland in upper and lower eyelids. Recently we developed a non-invasive meibography, and this triggered the expansion of meibomian gland research and clinics. Out of 121 ophthalmologists who belong to LIME, 25 use noncontact meibography, a morphological diagnostic tool [6,7], for the diagnosis of MGD in clinical practice. These 25 physicians were asked about the usefulness of meibography for the diagnosis of MGD and for the education of MGD patients (Figure 1). Of the 22 respondents to the question regarding the usefulness of meibography for diagnosis of MGD, 16 (72.7%) replied “notably” and 6 (27.3%) replied “some.” Of the 22 respondents to the question regarding the usefulness of meibography images for the education of MGD patients, 18 (81.8%) replied “notably” and 4 (18.2%) “some.” All respondents thus provided a positive response to both questions on the usefulness of meibography, indicating that meibography is recognized as a tool not only for diagnosis but also for patient education.

Eyelid warming

Then we asked ophthalmologists the efficacy of eyelid warming. Eyelid warming is a basic treatment for MGD recommended by Tear Film & Ocular Surface Society (TFOS). It is well-known that eyelid warming improved the tear film condition and ocular symptoms in MGD patients. Among the 121 ophthalmologists, 89 recommend a warming compress for the initial treatment of MGD in clinical practice. These 89 respondents were asked additional questions regarding this treatment, with 74 providing answers (Figure 2). With regard to the usefulness of eyelid warming as an initial treatment for MGD, 38 of the 74 respondents (51.4%) replied “valuable” and 36 (48.6%) selected “partly,” with all responses thus being positive. As to whether the use of a warming compress reduces the frequency of administration of eyedrops for dry eye, “notably,” “some,” “rarely,” and “none” were selected by 3 (4.1%), 50 (67.6%), 18 (24.3%), and 3 (4.1%)

respondents, respectively, with most responses thus again being positive. Of the 71 respondents who thought that a warming compress did reduce the frequency of eyedrop use, 2 (2.8%), 12 (16.9%), 27 (38.0%), and 30 (42.3%) estimated that it did so by >80%, 50-80%, 30-50%, or 10-30%, respectively, with ~60% of respondents thus estimating a reduced frequency of eyedrop administration of at least 30%. With regard to whether eyelid warming reduces the prescription of eyedrops by physicians, none of the 71 respondents selected “notably,” with 47 (66.2%), 21 (29.6%), and 3 (4.2%) selecting “some,” “rarely,” and “none,” respectively. Finally, of the 68 respondents who did not answer “none” to the previous question, 8 (11.8%), 24 (35.3%), and 36 (52.9%) thought that the use of a warming compress reduced the frequency of eye drop prescription by 50-80%, 30-50%, or 10-30%, respectively.

Lid hygiene

Finally, we asked the efficacy of lid hygiene to the ophthalmologists. Lid hygiene is a procedure to clean eyelids up with using shampoo or something like that. Lid hygiene is also recommended by TFOS as a basic care procedure as well as eyelid warming. Among the 121 ophthalmologists, 89 recommend the practice of lid hygiene for the initial treatment of MGD. These 89 respondents were asked additional questions regarding this treatment, with 60 providing answers (Figure 2). With regard to the usefulness of lid hygiene as an initial treatment for MGD, 38 (63.3%), 19 (31.7%), 3 (5.0%), and 0 (0%) of the 60 respondents answered “valuable,” “partly,” “elective,” or “unnecessary,” respectively, with all responses thus being positive. As to whether the practice of lid hygiene reduces the frequency of eyedrop use, 5 (8.3%), 36 (60.0%), 19 (31.7%), and 0 (0%) of the 60 responders selected “notably,” “some,” “rarely,” or “none,” respectively, with again all responses being positive. The extent of the reduction in the rate of eyedrop use was estimated as >80%, 50-80%, 30-50%, or 10-30% by 1 (3.2%), 9 (29.0%), 13 (41.9%), and 8 (25.8%) of the 31 respondents, respectively, with ~75% of respondents thus thinking that lid hygiene has the potential to reduce the frequency of eyedrop use by 30% or more. Two (3.3%), 39 (65.0%), 19 (31.7%), and 0 (0%) of 60 responders selected “notably,” “some,” “rarely,” or “none,” respectively, when asked whether lid hygiene reduces the prescription of eyedrops. Finally, 1 (3.2%), 9 (29.0%), 14 (45.2%), and 7 (22.6%) of 31 respondents selected >80%, 50-80%, 30-50%, or 10-30%, respectively, with regard to by how much lid hygiene reduces the frequency of eyedrop prescription, with ~80% of respondents thus estimating that the practice of lid hygiene has the potential to reduce the frequency by 30% or more.

Combination of eyelid warming and lid hygiene

We also asked physicians how often they recommend the combination of a warming compress and lid hygiene. Among the 60 responders, 31 (51.7%), 9 (15.0%), 9 (15.0%), and 11 (18.3%) selected >80%, 50-80%, 30-50%, or 10-30% of cases, respectively.

Discussion

With the use of a questionnaire, we evaluated the efficacy of meibography, eyelid warming, and lid hygiene for the diagnosis or management of MGD as estimated by ophthalmologists in clinical practice. The results indicated that meibography is a valued tool both for the diagnosis of MGD and for patient education. In addition, home care for MGD consisting of eyelid warming or lid hygiene was considered effective with regard to reducing the use and prescription of

eyedrops for dry eye. Our data thus suggest that adequate management of MGD independent of eyedrop treatment is beneficial for patients.

Self-care that includes patient education, eyelid warming, lid hygiene, and diet modification has been recommended as initial treatment for MGD [5], to be attempted before the prescription of eyedrops for amelioration of ocular symptoms. Our data now show that adequate self-care for MGD has the potential to reduce the

frequency of eyedrop use and prescription. In our personal experience, the prescription of eyedrops for MGD patients without self-care is often ineffective in clinical practice. The recommendation of self-care for MGD reduces time spent by patients in the clinic as well as the cost of treatment, and thus has the potential to reduce national healthcare costs overall.

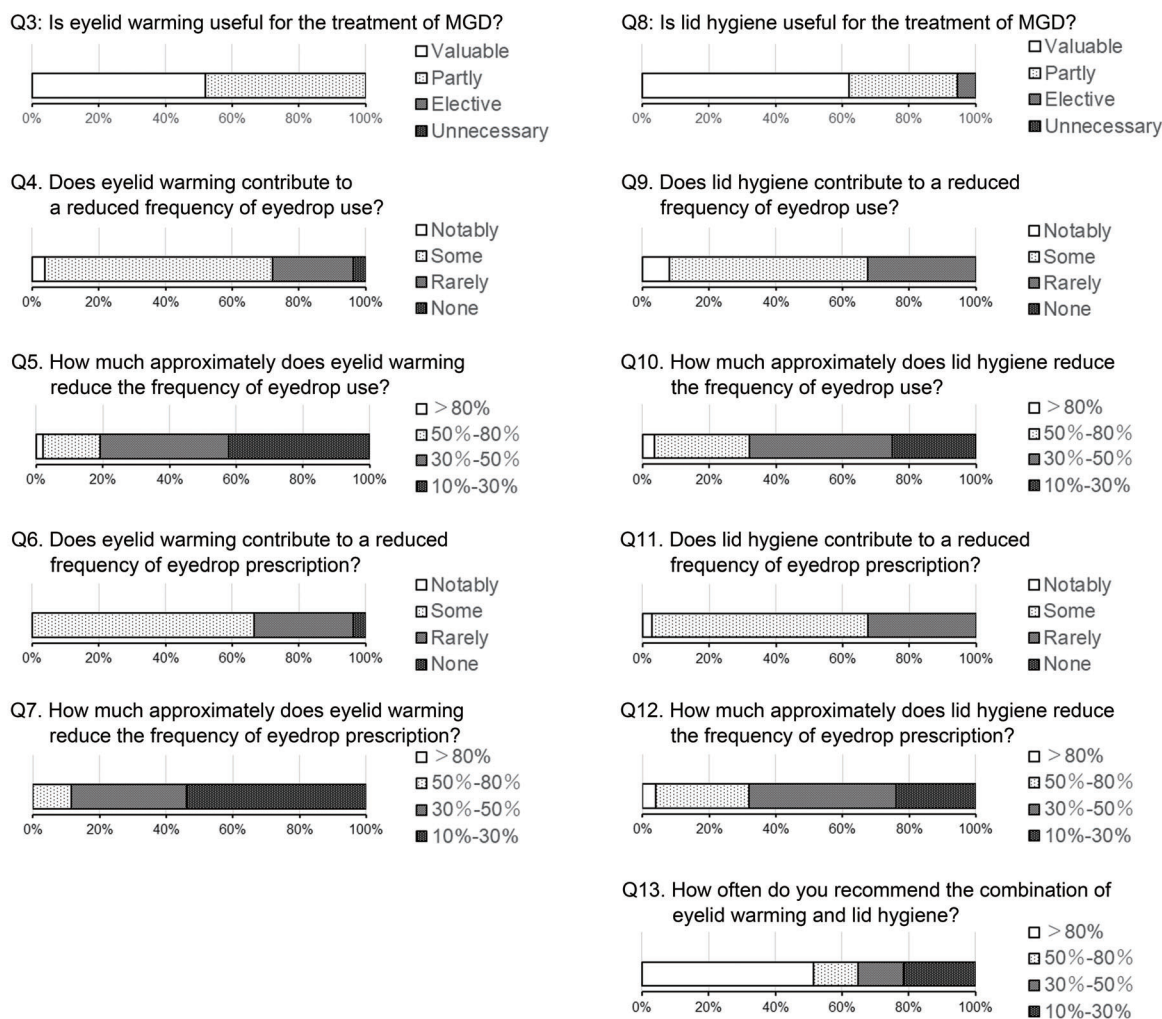


Figure 2: Responses to questions regarding the efficacy of eyelid warming and lid hygiene.

Our data indicate that noncontact meibography is a valuable tool for the diagnosis of MGD. This tool has been approved by the Ministry of Health, Labor, and Welfare and is widely applied in ophthalmic clinics in Japan, although it is not covered by national insurance. Meibography is also used to educate MGD patients with regard to their condition and to motivate them to administer self-care, with this application also being supported by the results of our questionnaire.

The impressions of ophthalmologists with regard to the efficacy of eyelid warming and lid hygiene as revealed in our questionnaire

support the recommendation of self-care for MGD patients [5]. In addition to other options such as eyedrops and oral tetracycline, several new approaches such as exposure to intense pulsed light [8] or thermal pulsation [9] have recently been introduced as treatment regimens for MGD. Although its recommendation may be hindered in some cases because it does not generate repeated income for ophthalmologists, our data suggest that self-care is an effective and low-cost treatment option for MGD. The assessment for the efficacy of eyelid warming and lid hygiene in multi-center would be performed in the future study to support the current results.

References

1. Mishima S, Maurice DM (1961) The oily layer of the tear film and evaporation from the corneal surface. *Exp Eye Res* 1: 39-45.
2. Nichols KK, Foulks GN, Bron AJ, Glasgow BJ, Dogru M, et al. (2011) The international workshop on meibomian gland dysfunction: executive summary. *Invest Ophthalmol Vis Sci* 52: 1922-1929.
3. Lemp MA, Crews LA, Bron AJ, Foulks GN, Sullivan BD (2012) Distribution of aqueous-deficient and evaporative dry eye in a clinic-based patient cohort: a retrospective study. *Cornea* 31: 472-478.
4. Arita R, Itoh K, Maeda S, Maeda K, Furuta A, et al. (2009) Proposed diagnostic criteria for obstructive meibomian gland dysfunction. *Ophthalmology* 116: 2058-2063e1.
5. Geerling G, Tauber J, Baudouin C, Goto E, Matsumoto Y, et al. (2011) The international workshop on meibomian gland dysfunction: report of the subcommittee on management and treatment of meibomian gland dysfunction. *Invest Ophthalmol Vis Sci* 52: 2050-2064.
6. Arita R, Itoh K, Inoue K, Amano S (2008) Noncontact infrared meibography to document age-related changes of the meibomian glands in a normal population. *Ophthalmology* 115: 911-915.
7. Arita R, Itoh K, Maeda S, Maeda K, Amano S (2013) A Newly Developed Noninvasive and Mobile Pen-Shaped Meibography System. *Cornea* 32: 242-247.
8. Toyos R, McGill W, Briscoe D (2015) Intense pulsed light treatment for dry eye disease due to meibomian gland dysfunction; a 3-year retrospective study. *Photomed Laser Surg* 33: 41-46.
9. Korb DR, Blackie CA (2013) Case report: a successful LipiFlow treatment of a single case of meibomian gland dysfunction and dropout. *Eye Contact Lens* 39: e1-3.